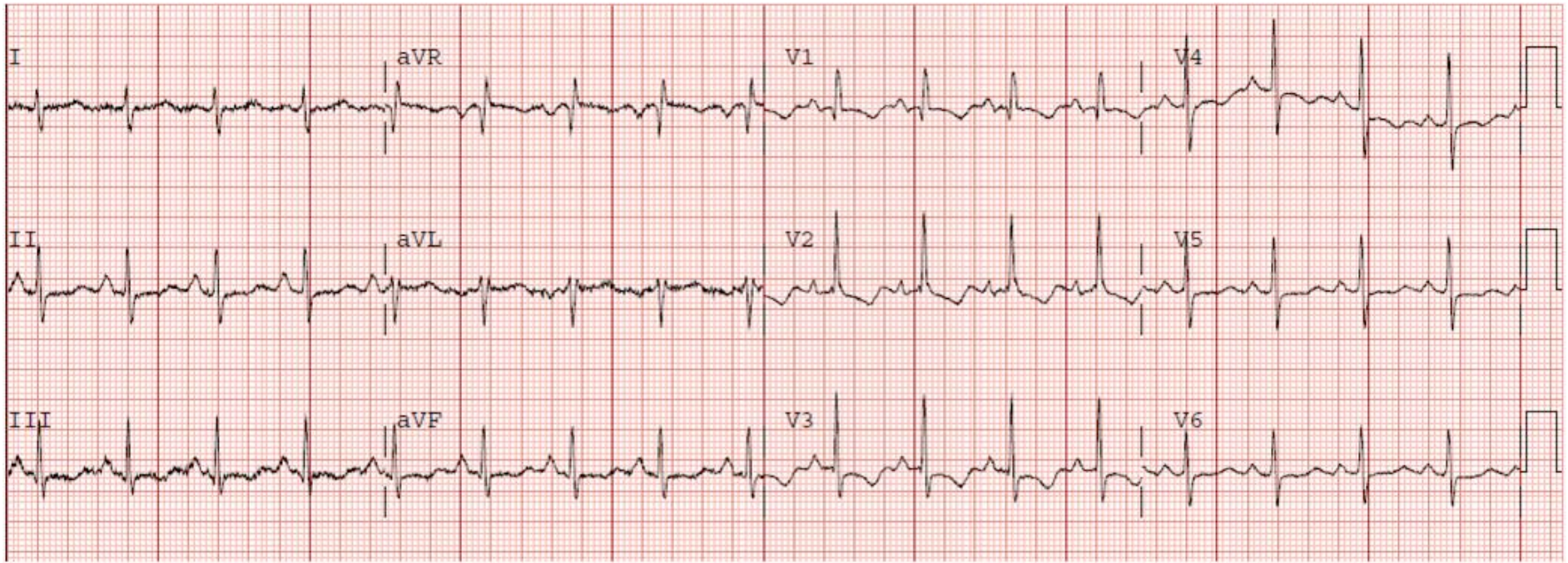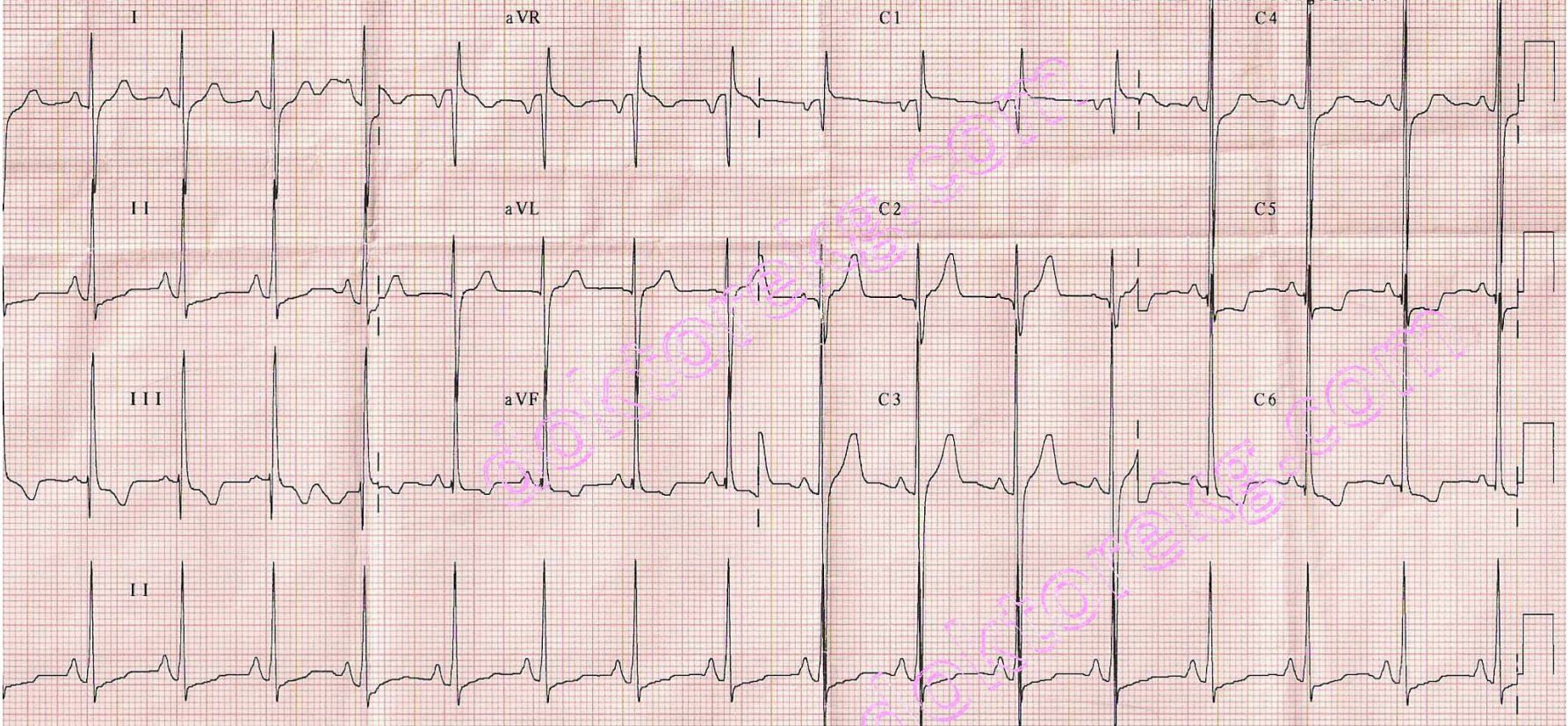


--Axis--
P 50
QRS 101
T -13

- ABNORMAL ECG -

Unconfirmed diagnosis.



Referring:

Technician:

Confirmed By: Tsai Albert

